

Thrombolysis in Acute Thrombosis of Metallic Mitral Valve - Case Report

Adnan Aslam, Qazi Abdul Saboor, Amber Malik, Adnan Saleem Malik and Imran Akhter
Department of Cardiology, Shaikh Zayed Postgraduate Medical Institute, Lahore

ABSTRACT

Prosthetic valve thrombosis is a potentially life-threatening complication associated with high morbidity and mortality. Transthoracic and transoesophageal echocardiography play an important role to the diagnosis and provides incremental information about the optimal treatment strategy, while fluoroscopy is a low-cost, noninvasive imaging technique, with limited radiation exposure that allows the correct evaluation of opening and closing angles and can add diagnostic value to echocardiography. Guidelines differ on whether surgical treatment or fibrinolysis should be the treatment of choice for the management of left-sided prosthetic valve thrombosis and these uncertainties underline the need for further prospective randomized controlled trials. Thrombus size, New York Heart Association functional class of the patient, the possible contraindications, the availability of each therapeutic option and the clinician's experience are important determinants for the management of prosthetic valve thrombosis.

INTRODUCTION

Prosthetic valve obstruction (PVO) is an infrequent but serious complication in patients with prosthetic heart valve and is associated with significant morbidity and mortality.^{1,2,3} It is frequently related to thrombus formation, secondary to pannus formation, and rarely to vegetation.³ Prosthetic valve thrombosis (PVT) has an incidence between 0.1% to almost 6% per patient-year of left-sided valves and up to 20% of tricuspid valves.⁴ PVT depends on valve type, anticoagulation status, valve position, the presence of atrial fibrillation, and/or ventricular dysfunction. The most common cause is an inadequate anticoagulant therapy.

CASE REPORT

Twenty seven years old lady, resident of Shujhabad, married, has 7 years old one daughter. She delivered a baby boy by C-section 6 months ago. She is known case of rheumatic heart disease S/P Mitral valve replacement 6 yrs ago with CarboMedics Bileaflet Mitral Prosthesis .She remained well post MVR and was on regular follow

up from Nishtar Hospital Multan.

She presented with H/O exertional dyspnea (NYHA II-III) for the last 20 days, orthopnea, PND (NYHA IV) for the last 3 days for which pt remained admitted in Nishtar Hospital Multan for 3 days. There was no history of fever. Pt was switched to half tablet of warfrin (2.5mg OD) on 1st day of admission after an INR of 4.1. Urgent transthoracic echocardiography was done on same day that showed prosthetic MV in situ with gross paravalvular leak. Pt was ultimately referred to SZH for further management.

On physical examination, she was oriented but dyspnoeic and restless. Her BP was 110/70, pulse 110/min (reg), respiratory rate 24/ min and temperature 98 F. All peripheral pulses are palpable. Precordium examination revealed median sternotomy scar and muffled prosthetic valve opening and closing clicks along with systolic murmur of grade 2/6 at the apical area radiating to axilla. Chest, Bibasal fine inspiratory crepts . Rest of the systemic examination was unremarkable.

She was hospitalized for further workup . Lab results showed: Hb 11.6, TLC 7.6, PLT 222, PT 19/13, APTT 26/30, INR 1.6. RFTs and LFTs are normal .Blood cultures was negative and ECG was

normal. Chest x-ray showed : Bilateral pulmonary congestion with prominence of pulmonary conus. Transthoracic echo was done on same day which showed prosthetic mitral valve *in situ*, severe pulmonary HTN and reduced excursion of both prosthetic leaflets .Mean transprosthetic gradient was 31mmHg indicating moderate to severe obstruction (Fig. 1). Transoesophageal echo was done on next day which also showed limited excursion of both prosthetic leaflets with mild valvular leak.

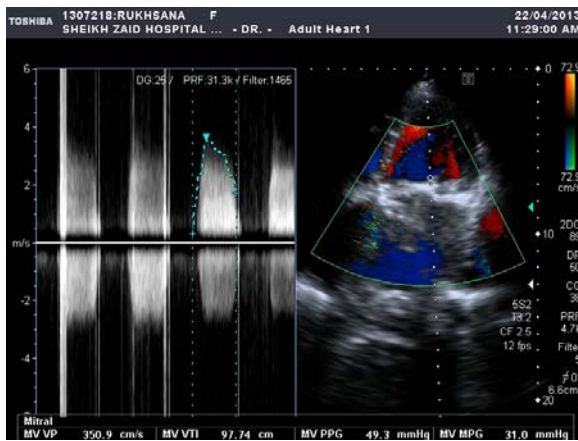


Fig. 1: Mean Gradient 31 mmHg indicating moderate to severe obstruction (pre SK).

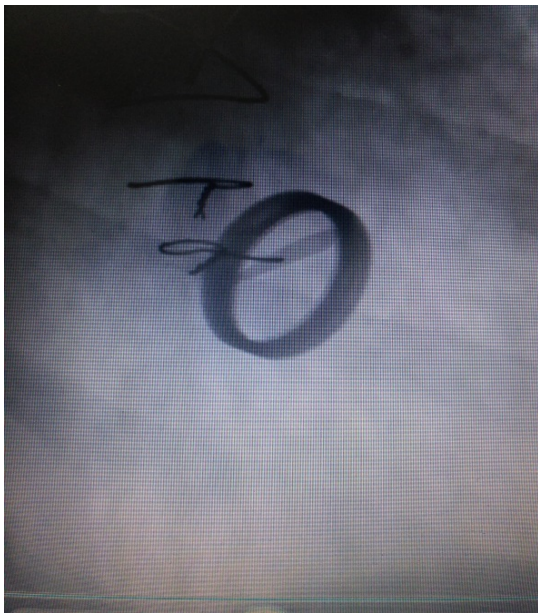


Fig. 2: Flouroscopy showing only one disc (pre SK)

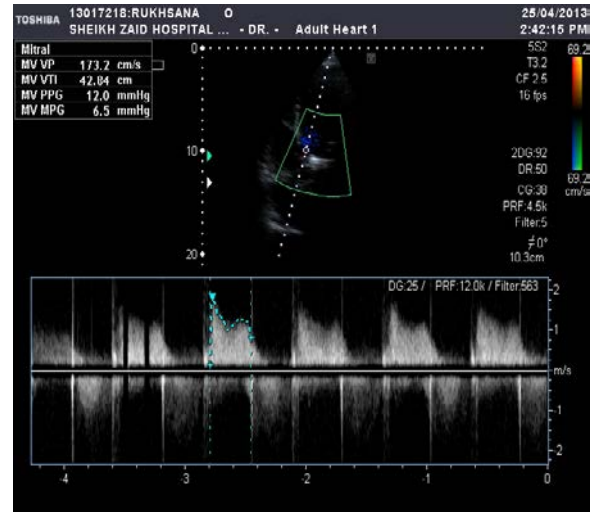


Fig. 3: MPG 6.5mmHg (post SK)

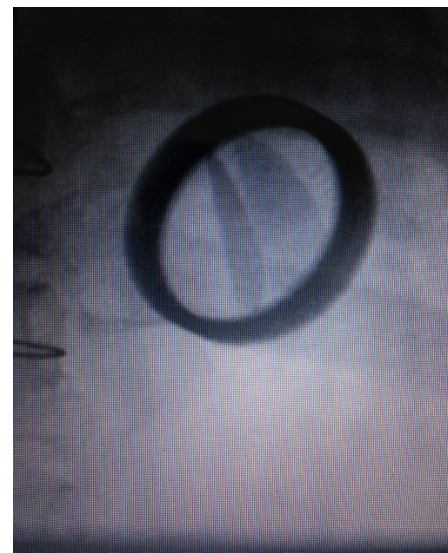

Fig. 4: Both discs visible (post MV Thrombolysis)

During her hospitalization she developed sudden worsening SOB associated with cold profuse sweating and restlessness. On physical examination: BP 80/50, Pulse 136/min (reg & low vol), Cold peripheries, absent prosthetic valve clicks with bilateral crepts upto apices. Pt was shifted to cath lab for cineflouroscopy. Under RAO cranial projection only one disc was visible but with very limited motion (Fig. 2). Based on clinical parameters and fluoro images decision was made for rescue thrombolysis. Injection Streptokinase given with a dose of 250,000 unit i/v over 20 mins

followed by 1.5 million units i/v over next 10 hours followed by heparin infusion for the next 72 hours. There was a dramatic response post s.k with significant improvement clinically, patient become hemodynamically stable and prosthetic clicks become audible. Transthoracic and transeoesophageal echo was done post thrombolysis which showed significant reduction in the transprosthetic gradients (mean gradient 6.5 mmHg) (Fig. 3) and much improvement in the mobility of anterior mitral leaflet. Fluoroscopy was also done which still showed only one disc/leaflet but with much improved motion. Cardiothoracic consultation was taken as patient has still stucked one leaflet despite thrombolysis so ultimately decision was made for redosurgery or MV repair. The patient underwent MV repair by removing the pannus producing impingement on posterior mitral leaflet. Peroperative transoesophageal echo was done which showed good mobility of both prosthetic leaflets with normal gradients. Transthoracic and transoesophageal echo was done post MV repair which showed the normal excursion of both leaflets with normal tranvalvular gradients. Cinefluoroscopy was also done post MV repair which showed both discs with normal opening and closing angles (Fig.4).

She was discharged after 5 days and was advised to continue warfarin 5mg with target INR (2.5-3.5). Her further regular follow up visits showed sustained improvement with optimal INR achievement.

DISCUSSION

PVT is mostly a complication of mechanical valves, while pannus formation is common to both bioprostheses and mechanical valves.⁵ Reasons for the increased thrombogenicity of mechanical valves are the interaction of blood constituents such as platelet and blood cells first with injured endocardium immediately after the surgery, secondly with the surface of the mechanical valve that has thrombogenic properties leading to both platelet deposition and activation of factor XII, and thirdly with structural and metabolic changes due to irregular flow patterns arising around the prosthetic devices.^{6,7} Thrombus formation usually begins at the

hinges of mechanical valves.⁸ Increased incidence of thrombotic events up to 10% have been reported in the first 3–6 months after implantation of the valve mainly in the mitral position. This can be explained by the hypercoagulable state after surgery and the contact of bloodstream with the nonendothelialized thrombogenic surfaces particularly on suture sites and prosthesis material.⁹ Bioprosthetic valves have a considerably less frequency of thrombosis, approximately 0.03% per year mainly seen in the first months following surgery while the sewing ring becomes endothelialized.^{10,11}

Obstructive PVT (OPVT) can present along a wide spectrum that includes systemic embolism, the insidious onset of fatigue, and shortness of breath developing over weeks to acute haemodynamic deterioration and death.² Patients with nonobstructive thrombi (NOPVT) present minimal clinical symptoms and they are stable but they constitute a group of high embolic potential.¹³ Distinction between thrombus and pannus formation based on clinical grounds may be difficult. Generally, patients with thrombus formation have shorter duration of symptoms and more often inadequate anticoagulation.¹² In the clinical suspicion of endocarditis, blood cultures should be performed to exclude this entity. Although physical examination is frequently insufficient, it can reveal decreased prosthetic valve sounds, a new murmur, or change in a previously detected murmur. Pannus formation is fibroconnective tissue ingrowth from the sewing ring and typically occurs after many years of valve implantation. Its formation is unaffected by routine anticoagulation.¹² It is generally considered as a bioreaction to the prosthesis and occurs more often on aortic mechanical prostheses as well as around the prosthetic ring after mitral repair. A thrombus layer can be formed secondarily on a pannus.

The examination of a patient with prosthetic cardiac valve by Transthoracic echocardiography is an essential part of diagnostic assessment.^{14,15} Transthoracic examination can be limited because the prosthesis produces a certain degree of acoustic shadowing caused by the highly reflective material itself and characteristic reverberations which need to be distinguished from vegetation or a thrombus.

Doppler echocardiography is the most accurate method for detecting and quantifying the degree of transvalvar gradient. Transoesophageal echocardiography can help to assess thrombus size and location by its high-resolution imaging and can aid in treatment decisions, such as thrombolysis, anticoagulation, and surgery.¹⁵ The exact visualization of mechanical prosthetic heart valve leaflet motion is best achieved by cinefluoroscopy. It is a low-cost, noninvasive imaging technique, with limited radiation exposure that allows the correct evaluation of opening and closing angles and the motion of the base ring of the prosthetic heart valve and can add diagnostic value to echocardiography.¹⁶

Thrombolysis and redosurgery (valvular replacement or repair) are widely accepted options for treatment of prosthetic valvular thrombosis.¹⁹ Immediate success rate, major adverse events and peri-procedural mortality are comparable. In haemodynamically unstable patients, the risk for major complications increases to the same extent for both procedures. Reoperation constitutes a more definitive treatment, with complete and thorough removal of thrombotic material. It also allows close inspection of the thrombosed valve, which enables identification of the valve related factors that may predispose to recurrent thrombosis. Thrombolysis serves to avoid a second operation, although this may still be necessary if thrombolysis fails. Until randomized clinical trials are performed, there is no evidence that either of the two treatment options offers any substantial advantage over the other. It is therefore advisable to tailor therapy according to the preferences of the individual patient and the experience of the managing physicians. Thrombolysis is certainly more cost-effective than reoperation; this is an important consideration in developing countries, where a substantial number of patients cannot afford a second operation.^{17,18} Treatment with intravenous heparin for 48 h, followed by a combination of subcutaneous heparin and oral anticoagulation on an outpatient basis, should be restricted to patients with non-obstructive thrombosis and a stable clinical condition (NYHA class I or II). Close clinical surveillance is mandatory. Therapeutic decision making must take

into account all the circumstances specific to the individual patient.¹⁹

REFERENCES

1. Roudaut R, Serri K and Lafitte S. Thrombosis of prosthetic heart valves: diagnosis and therapeutic considerations. *Heart* 2007; 93: 137–42.
2. Daniels CJ, Barbetseas J and Boudoulas H. Prosthetic valves. In: ACC (eds) *Adult clinical cardiology self-assessment program*, version 7. Washington, DC, American College of Cardiology, 2009, book 4, chapter 19, pp. 19.9.1–19.9.25
3. Deviri E, Sareli P, Wisenbaugh T, et al. Obstruction of mechanical heart valve prostheses: clinical aspects and surgical management. *J Am Coll Cardiol* 1991; 17: 646–50.
4. Vahanian A, Baumgartner H, Bax J, et al. Guidelines on the management of valvular heart disease: The Task Force on the Management of Valvular Heart Disease of the European Society of Cardiology. *Eur Heart J* 2007; 28: 230–68.
5. Butchart EG. Antithrombotic management in patients with prosthetic valves: a comparison of American and European guidelines. *Heart* 2009; 95: 430–36.
6. Yin W, Alemu Y, Affeld K, et al. Flow-induced platelet activation in bileaflet and monoleaflet mechanical heart valves. *Ann Biomed Eng* 2004; 32: 1058–66.
7. Leguyader A, Watanabe R, Berbé J, et al. Platelet activation after aortic prosthetic valve surgery. *Interact Cardiovasc Thorac Surg* 2006; 5: 60–4.
8. Girdhar G and Bluestein D. Biological effects of dynamic shear stress in cardiovascular pathologies and devices. *Expert Rev Med Device* 2008; 5: 167–81.
9. Sun JC, Davidson MJ, Lamy A, et al. Antithrombotic management of patients with prosthetic heart valves: current evidence and future trends. *Lancet* 2009; 374: 565–76.
10. Grunkemeier GL, Li HH, Naftel DC, et al. Long-term performance of heart valve

- prostheses. *Curr Probl Cardiol* 2000; 25: 73–154.
11. Aminian A, Lefebvre P, Delmotte P, et al. An unusual case of late bioprosthetic mitral valve thrombosis successfully managed with anticoagulation. *Eur J Echocardiogr* 2008; 9: 399–400.
 12. Barbetseas J, Nagueh SF, Pitsavos C, et al. Differentiating thrombus from pannus formation in obstructed mechanical prosthetic valves: an evaluation of clinical, transthoracic and transesophageal echocardiographic parameters. *J Am Coll Cardiol* 1998; 32: 1410–17.
 13. Laplace G, Lafitte S, Labèque JN. et al. Clinical significance of early thrombosis after prosthetic mitral valve replacement: a postoperative monocentric study of 680 patients. *J Am Coll Cardiol* 2004; 43: 1283–90.
 14. Barbetseas J and Zoghbi WA. Evaluation of prosthetic valve function and associated complications. *Cardiol Clin* 1998; 16: 505–30.
 15. Zoghbi WA, Chambers JB, Dumesnil JG, et al. Recommendations for evaluation of prosthetic valves with echocardiography and doppler ultrasound. *J Am Soc Echocardiogr* 2009; 22: 975–1014.
 16. Barbetseas J, Crawford ES, Safi HJ, et al. Doppler echocardiographic evaluation of pseudoaneurysms complicating composite grafts of the ascending aorta. *Circulation* 1992; 85: 212–22.
 17. Barbetseas J, Pitsavos C, Aggeli C, et al. Comparison of frequency of left atrial thrombus in patients with mechanical prosthetic cardiac valves and stroke versus transient ischemic attacks. *Am J Cardiol* 1997; 80: 526–28.
 18. Tong AT, Roudaut R, Ozkan M, et al. Transesophageal echocardiography improves risk assessment of thrombolysis of prosthetic valve thrombosis: results of the international PRO-TEE registry. *J Am Coll Cardiol* 2004; 43:77–84.
 19. Capdeville M and Licina M. Assessment of prosthetic valves. In: Savage R and Aronson S (eds) *Intraoperative transesophageal echocardiography*. 1st ed. Philadelphia: Lippincott Williams & Wilkins, 2005, pp. 249–69.
 20. Symersky P, Budde RP, De Mol BA, et al. Comparison of multidetector-row computed tomography to echocardiography and fluoroscopy for evaluation of patients with mechanical prosthetic *Am J Cardiol* 2009; 104:1128–34.

The Authors:

Mohammad Adnan Aslam
Trainee Registrar
Department of Cardiology
Shaikh Zayed Postgraduate Medical Institute,
Lahore, Pakistan.

Qazi Abdul Saboor
Assistant Professor
Department of Cardiology
Shaikh Zayed Postgraduate Medical Institute,
Lahore, Pakistan.

Amber Malik
Professor
Department of Cardiology
Shaikh Zayed Postgraduate Medical Institute,
Lahore, Pakistan

Adnan Saleem Malik
Trainee Registrar
Department of Cardiology
Shaikh Zayed Postgraduate Medical Institute,
Lahore, Pakistan.

Imran Akhter
Trainee Registrar
Department of Cardiology
Shaikh Zayed Postgraduate Medical Institute,
Lahore, Pakistan.

Corresponding Author:

Mohammad Adnan Aslam
Trainee Registrar
Department of Cardiology
Shaikh Zayed Postgraduate Medical Institute,
Lahore, Pakistan.

